

The Use of the LUTONIX[®] 035 Drug Coated Balloon PTA Catheter for Challenging AV Access Stenosis

Formulating a strategy to manage neointimal hyperplasia for dysfunctional AV fistulas in clinical practice.

BY THEODORE F. SAAD, MD

The role of neointimal hyperplasia in the failure of arteriovenous (AV) access has been firmly established over many decades. Conventional balloon angioplasty (percutaneous transluminal angioplasty [PTA]) has long been the standard of care for minimally invasive treatment of stenosis. However, angioplasty does nothing to interrupt the fundamental pathophysiology of neointimal hyperplasia and, in fact, may accelerate the process due to injury-induced mediators of cellular proliferation. Drug-coated balloon (DCB) angioplasty, particularly with the antiproliferative agent paclitaxel, has been shown to reduce neointimal hyperplasia and reduce lesion restenosis in a variety of vascular applications. Clinical studies have demonstrated outcome benefit when DCBs are used to treat stenosis occurring in AV access.¹ The recently completed Lutonix AV clinical trial demonstrated a significant reduction in the frequency of reintervention after DCB PTA, consistent with paclitaxel's known mechanism of action.² The LUTONIX[®] 035 DCB (BD) extended the time to reintervention by 114 more days at 24 months when compared to PTA.³ There was also a signal of improved target lesion primary patency at 6 months (71.4% for DCB vs 63.0% for PTA).² However, this did not meet statistical significance at the study-prescribed endpoint. The Lutonix AV study enrolled lesions throughout the access circuit; some of these were likely not responsive to antiproliferative treatment, whereas others may have benefited substantially from reduction in neointimal hyperplasia. Subgroup analysis appears to support this, with superior response in lesions treated for recurrent stenosis; these observations are limited by small sample sizes and statistical challenges of post hoc analysis. Nevertheless, the Lutonix AV trial results can inform a rational strategy for using DCBs in clinical practice.

CLINICAL PARADIGM

Our current paradigm is geared toward identifying lesions most likely to be associated with accelerated neointimal hyperplasia and manifest by rapid restenosis (< 3 months) after previous PTA. Preprocedure ultrasound is a useful tool that can demonstrate a thickened vessel wall at the site of stenosis (Figure 1). Lesions at the arterial anastomosis, juxta-anastomotic segment, needle cannulation areas, and vein transposition swing segments are particularly attractive for DCB PTA treatment. Other sites, such as the cephalic arch or central veins, are more difficult to attribute to hyperproliferative behavior and may have local mechanical factors or elasticity driving stenosis, making other treatment options potentially more attractive.

In my practice, numerous patients appear to have benefited significantly from DCB PTA when managed according to this paradigm. One such example is a 69-year-

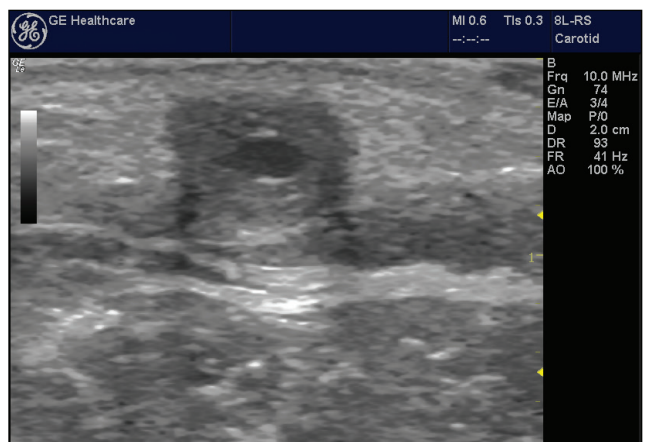


Figure 1. Stenosed AV fistula (AVF) with thickened vein wall indicative of neointimal hyperplasia.

Sponsored by BD

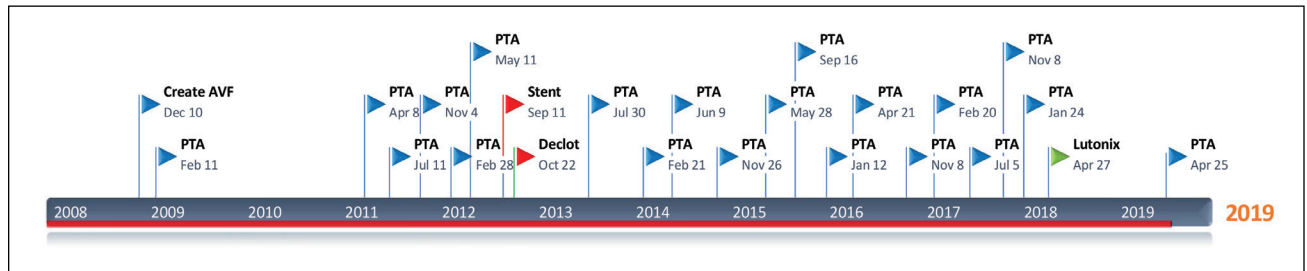


Figure 2. Time of access history and interventions.

old man with end-stage renal disease (ESRD) due to autosomal-dominant polycystic kidney disease requiring renal replacement therapy for over 30 years. He first initiated treatment with peritoneal dialysis but developed permanent technique failure due to complicated peritonitis. He underwent two successful kidney transplantations, both of which ultimately failed, requiring him to return to hemodialysis in 2007 using a basilic vein transposition AVF. Between 2008 and 2018, this fistula required 21 separate interventions (Figure 2) with conventional angioplasty, including one stent graft and one thrombectomy. He has no other suitable veins for construction of a new AVF and has chronic hypotension, limiting the potential for a successful prosthetic graft. His fistula, although arguably “high maintenance,” is a precious vascular access, which embodies the concept of the dialysis patient “lifeline.” During 2017 and 2018, he required five angioplasties for stenosis of the fistula inflow and puncture segments (Figure 3A), each time with acceptable immediate result (Figure 3B) using a conventional PTA balloon (VACCESS® or CONQUEST®, BD). Each angioplasty was followed by rapid, functionally significant restenosis (mean interval, 107 days). He then was considered for DCB PTA. Ultrasound demonstrated a thick ring of tissue, indicating severe intimal

hyperplasia (Figure 1), and angiography demonstrated recurrent stenosis at the same fistula segments (Figure 4A). Angioplasty was performed using an 8-mm X 4-cm VACCESS® balloon, followed by an 8-mm X 6-cm LUTONIX® 035 Drug Coated Balloon PTA Catheter (Figures 4B and 4C). Over the subsequent 12 months, he experienced no clinically significant AVF dysfunction, with stable monthly access flow measurements and no requirement for re-study or intervention. Ultimately, 363 days after DCB PTA, he was referred back for re-study due to falling access flow and difficulty with needle access, an interval more than three times longer versus previous conventional PTA treatments (Figure 5). Not surprisingly, he was keenly aware of his improved course after DCB PTA and stated, “I want that balloon again!”

Similarly, impressive clinical scenarios have been seen in other patients, lending strong observational support to the efficacy of DCB PTA in AVF stenosis. So, why did the Lutonix AV clinical trial not show a statistically significant improvement in lesion primary patency at 6 months? Based on personal experience, I believe the most likely explanation is that there were at least two distinct patterns of lesion behavior: those that derived little or no benefit from DCB versus those that had substantial benefit, akin

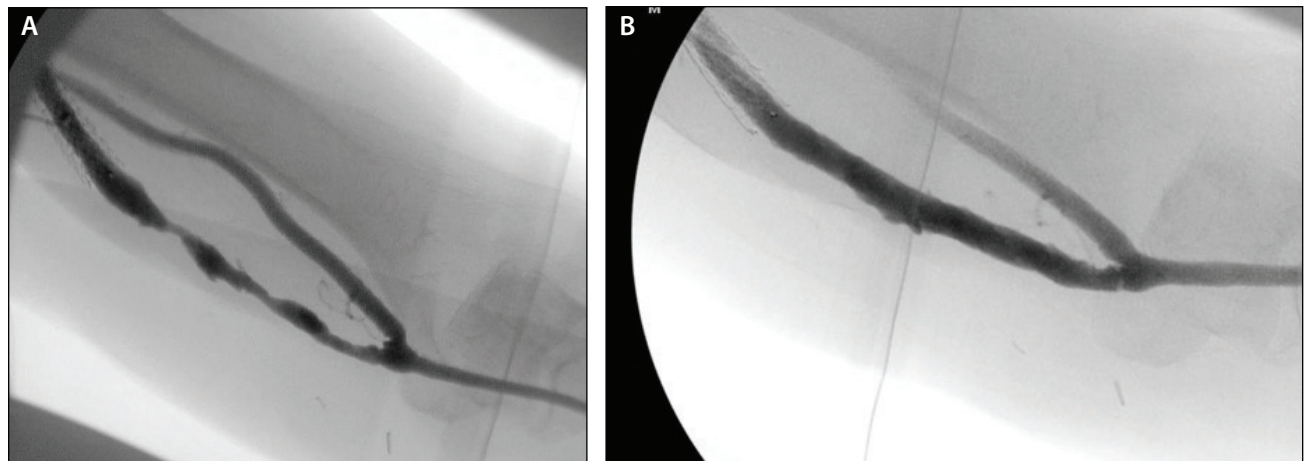


Figure 3. Basilic vein fistula puncture segment stenosis. Preangioplasty (A) and post 8-mm conventional balloon angioplasty (B).




Figure 4. Basilic vein fistula puncture segment restenosis. Preangioplasty (A). Post 8-mm X 4-cm VACCESS® balloon angioplasty (B). Post 8-mm X 6-cm LUTONIX® 035 DCB angioplasty (C).

to the patient presented in this case. Clearly, the next step must be to identify and characterize those subgroups most likely to benefit from DCB. Ultrasound visualization of vessel wall morphologic changes of neointimal hypertrophy is a promising method to identify lesions that are potentially more responsive to paclitaxel’s antiproliferative effects.⁴

SAFETY

The Lutonix AV trial was designed to examine safety at 30 days, demonstrating no difference with DCB versus conventional PTA (95.0% and 95.8%, respectively) with regard to freedom from primary safety events.⁵ Subsequent analysis at 2 years also demonstrated no significant difference in mortality between the groups (23.4% with DCB vs 18.1% with conventional PTA; $P = .265$).³ It should also be noted that among FDA-approved paclitaxel-coated balloons, the LUTONIX® 035 DCB Catheter is the only DCB approved for use in AV access in the United States and has a low surface concentration of paclitaxel at 2 µg/mm², carried in a polysorbate and sorbitol excipient. In my opinion, it is reasonable to utilize this low effective dose of paclitaxel in AV access applications, where recurrent stenosis and retreatment are likely.

AV access complications contribute disproportionately to morbidity and mortality in these patients. ESRD patients in the United States have exceedingly high mortality, with a 2-year mortality rate of 33.2%.⁶ In our practice, we have adopted an approach to consenting for use of DCBs in AV access patients. We disclose the information relative to peripheral artery disease and the absence of clinical evidence for higher risk in AV access; we document this discussion in the consent and/or procedure report. Presented in this way, we have not yet seen a patient with recurrent fistula stenosis decline the opportunity for DCB PTA.

COST-EFFECTIVENESS

No discussion of the clinical application of DCB technology for AV access would be complete without addressing the economic factors involved. For my patient who said, “I want that balloon,” we need a system that will cover the additional cost of a DCB, in order to reap the downstream clinical benefits and cost savings of reduced intervention frequency. Unfortunately, in office-based interventional facilities and ambulatory surgery centers, reimbursement for angioplasty is insufficient to support the added cost of a DCB. Therefore, DCB usage is effectively

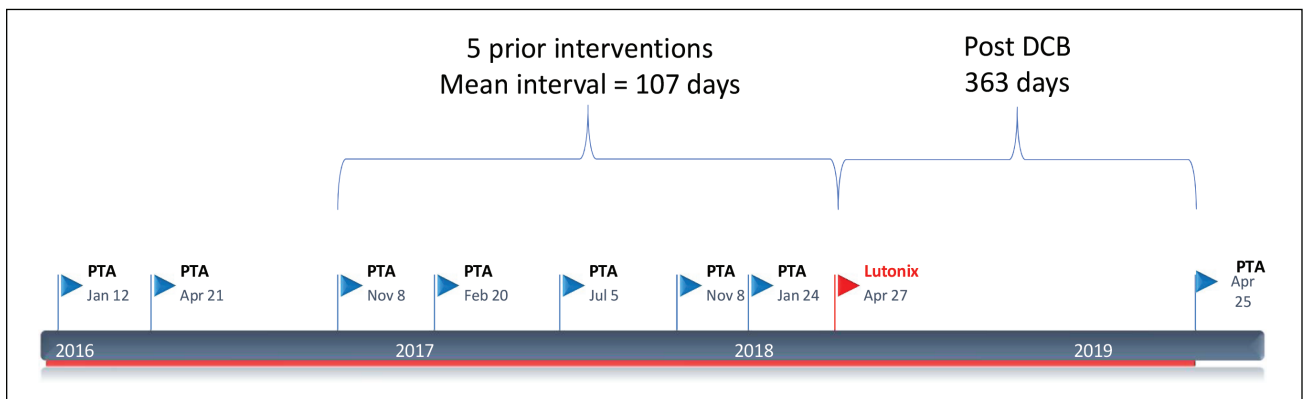


Figure 5. Access timeline: “accelerated phase” of restenosis preceding DCB angioplasty and subsequent extended intervention-free interval.

Sponsored by BD

restricted to hospital-based interventional programs, where higher reimbursement can accommodate the use of this technology. Important “wild cards” in this system are the shared-risk entities, such as ESRD Seamless Care Organizations (ESCOs). There is a mismatch of incentive and reward built into the system, whereby the entity that invests in the DCB reaps no reward on that investment and in fact loses economically, whereas the patient, payer, dialysis facility, and ESCO all benefit from the investment. DCB treatment of AV access stenosis will not achieve its full potential until and unless these economic misalignments are remedied.

CONCLUSIONS AND RECOMMENDATIONS

1. For treating neointimal hyperplasia, which is the fundamental pathophysiology of AV access stenosis and failure, the LUTONIX® 035 DCB is the first and only paclitaxel-coated balloon approved for AV access available in the United States.
2. Use of the LUTONIX® 035 DCB Catheter in the Lutonix AV trial reduced the requirement for subsequent reinterventions by 114 days at 24 months; in my opinion, this statistically significant improvement may be amplified in selected lesions in which exuberant neointimal proliferation results in rapid, repeated restenosis.
3. In my experience, it is useful to monitor individual patient response post-DCB, in terms of need for early or multiple reinterventions. In practice, the patients effectively serve as their own controls for comparison of conventional versus DCB PTA outcomes. Further studies targeted to selected high-risk restenosis patients are needed.
4. DCBs should be preferred for lesions that are unsuitable for treatment with a stent graft and not readily amenable to surgical revision.
5. DCB technology has the potential for significant cost-effectiveness by reducing the requirement for multiple reinterventions. Wider adoption of DCB PTA will require a realignment of medicoeconomic factors, such that the entity investing in a DCB also derives the benefit of future cost savings; most practice in the United States is currently structured with the exact opposite incentives. ■

In August 2019, the U.S. Food and Drug Administration (FDA) issued an updated letter to health care providers noting an increased risk in late mortality (2-3 years post-treatment) with paclitaxel-coated devices when used to treat peripheral arterial disease in the femoropopliteal artery as compared with the use of non-drug coated devices. There is uncertainty regarding the magnitude and mechanism for the increased late mortality risk, including the impact of repeat paclitaxel-coated device exposure. Physicians should discuss this late mortality signal and the benefits and risks of available treatment options with their patients. BD will continue to work collaboratively with FDA and industry for additional safety data collection and inform labeling as appropriate. These communications as well as information about the FDA Panel meeting can be found at: <https://www.fda.gov/medical-devices/letters-health-care-providers/august-7-2019-update-treatment-peripheral-arterial-disease-paclitaxel-coated-balloons-and-paclitaxel>.

The opinions and clinical experiences presented herein are for informational purposes only. The results from this case study may not be predictive for all patients. Individual results may vary depending on a variety of patient-specific attributes.

1. Kitrou PM, Spiliopoulos S, Katsanos K, et al. Paclitaxel-coated versus plain balloon angioplasty for dysfunctional arteriovenous fistulae: one-year results of a prospective randomized controlled trial. *J Vasc Interv Radiol.* 2015;26:348-354.
2. Trerotola S, Roy-Chaudhury P, Lawson J, Saad T. Drug coated balloon angioplasty in failing AV fistulae: a randomized controlled trial. *Clin J Am Soc Nephrol.* 2018;13:1215-1224.
3. Trerotola S. DCBs: should I be using them and is it worth the cost? Presented at: Society of Interventional Radiology annual scientific meeting; March 23–28, 2019; Dallas, Texas.
4. Steiner K. Pathophysiology of stenosis within AV fistulas and mechanisms of PTA. *Endovasc Today.* 2016;15:28-31.
5. Lutonix® 035 DCB PTA Catheter [instructions for use]. Tempe (AZ): Bard Peripheral Vascular, Inc.; 2018. <https://www.crbard.com/CRBard/media/ProductAssets/BardPeripheralVascularInc/PF10608/en-US/s0brn5lov9n402q5w1v1x6fv066wk71tl.pdf>. Accessed August 16, 2019.
6. 2018 United States Renal Data System (USRDS) annual data report. Chapter 5: mortality. *Am J Kidney Dis.* 2019;73(suppl 1):411-426.

Theodore F. Saad, MD

Nephrology Associates Vascular Access Center
Newark, Delaware
tsaad@delawarekidney.com

Disclosures: Consultant to BD; investigator, Lutonix AV trial.